

## Facing COVID-19 in ICU: vascular dysfunction, thrombosis, and dysregulated inflammation

Daniel E. Leisman MD,<sup>1</sup> Clifford S. Deutschman MD, MS, MCCM,<sup>2</sup> and Matthieu Legrand MD, PhD<sup>3</sup>

<sup>1</sup> Icahn School of Medicine at Mount Sinai, New York, New York

<sup>2</sup> Departments of Pediatrics, Molecular Medicine and Surgery, Cohen Children's Medical Center, Feinstein Institute for Medical Research, Northwell Health, Manhasset, New York

<sup>3</sup> Department of Anesthesiology and Peri-Operative Medicine and Critical Care Medicine, University of California, San Francisco, California.

*This article has undergone peer-review and has been accepted for publication in the Journal Intensive Care Medicine (ICM). This is not yet the definitive version of the manuscript as it will undergo copyediting and typesetting before it is published in its final form with a DOI.*

**DOI: [10.1007/s00134-020-06059-6](https://doi.org/10.1007/s00134-020-06059-6)**

**Corresponding author:** Matthieu Legrand, Department of Anesthesiology and Perioperative Care, University of California, San Francisco, United States. e-mail address: [matthieu.legrand@ucsf.edu](mailto:matthieu.legrand@ucsf.edu)

Current management guidelines for COVID-19 reflect the assumption that critically ill patients infected with SARS-CoV-2 develop acute respiratory distress syndrome (ARDS). However, emerging data and clinical reports increasingly suggest an alternative view that severe COVID-19 reflects a confluence of vascular dysfunction, thrombosis, and dysregulated inflammation.

## **SEVERE COVID-19 IS DISTINCT FROM ARDS AND CYTOKINE-RELEASE SYNDROMES**

Published data,<sup>1,2</sup> anecdotal observations and discussions with colleagues worldwide indicate that COVID-induced respiratory phenotypes are distinct from typical ARDS in several ways.<sup>2</sup> COVID-19 patients develop profound hypoxemia early in their disease course. However, overt respiratory dysfunction at these early stages is unusual. Pulmonary compliance in intubated COVID-19 patients appears to be only modestly decreased and patients are therefore relatively easy to ventilate.<sup>1</sup> Gattinoni *et al.* described hyper-perfusion of poorly ventilated lung, perhaps due to vasodilation and the loss of hypoxic vasoconstriction.<sup>1</sup> While benefit from low-to-moderate levels of PEEP and prone positioning have been noted, these authors suggest that they result more from hemodynamics effects than lung recruitment.<sup>1</sup> Later in the course of COVID-19, some patients develop a phenotype more consistent with ARDS.<sup>1,2</sup>

The reported inflammatory response in COVID-19 is also not consistent with either typical ARDS or with cytokine-release syndromes (CRS) or “cytokine storm”. Qin *et al.* report mean interleukin-6 levels were 25 (SD:10-55) pg/mL (normal-range: 7pg/mL).<sup>3</sup> Other smaller COVID-19 reports have ranged from 7pg/mL to 125pg/mL. These findings contrast with interleukin-6 elevations

seen in typical ARDS and in CRS. Sinha *et al.* report mean interleukin-6 levels of 282 (111-600) pg/mL in “hypo-inflammatory” ARDS<sup>9</sup> and 1,618 (517-3,205) pg/mL in hyper-inflammatory ARDS,<sup>4</sup> 10 to 60-fold higher than reported in the Wuhan data. Among CRS patients, mean interleukin-6 levels are frequently as high as 10,000 pg/mL.<sup>5</sup> Other inflammatory cytokines (e.g., interleukin-8, interleukin-1 $\beta$ ) demonstrate similar patterns. In summary, COVID-19 is associated with only mild inflammatory cytokine elevation and demonstrates physiology and immunology that are difficult to reconcile with ARDS or CRS. An alternative mechanism of disease therefore seems likely.

### **VASCULOPATHY AND DYSREGULATED INFLAMMATION IN COVID-19**

The combination of observed physiology and emerging pathologic evidence point toward a vascular disease process as contributing factor in COVID-19 pathogenesis. Pulmonary shunting is consistent with intense vasodilation and endothelial dysfunction. The observation that 89% of hospitalized patients in Rome showed subsegmental vascular enlargement on their admission computed-tomography scan supports this view.<sup>6</sup> Reports of increased respiratory dead space suggest lung vascular thrombosis from thrombotic microangiopathy or pulmonary embolism. The latter was recently reported in up to 40% of hospitalized COVID-19 patients.<sup>7</sup> Autopsies performed on patients who died early on were indeed notable for lung-vascular congestion.<sup>8</sup> Vascular disease may also explain massive D-dimer elevations while antiphospholipid antibodies were recently reported in COVID-19.<sup>9</sup> A constellation of multi-system organ involvement, low-grade inflammation, lymphopenia, hypercoagulability, and heterogenous microvascular dysfunction is a classic description of many systemic vasculopathies, such as vasculitides (Supplement Table).

Reported findings indicate that immunosuppression, endothelial activation, and direct viral-mediated tissue damage, rather than hyper-inflammatory injury, mediate COVID-induced organ dysfunction. For example, a recent autopsy study found no renovascular or interstitial inflammation, but noted endothelial activation, occasional frank necrosis, and copious virions in renal tissue.<sup>10</sup> If direct infection drives injury, vascular tissue is expected to be quite susceptible as it highly expresses angiotensin-converting enzyme-2 (ACE-2), which is essential for coronavirus uptake.

SARS-CoV-2 initiates cellular infection by binding ACE-2 on the surface of human cells, including endothelial cells (Figure).<sup>11</sup> Attachment promotes disordered cytokine paracrine signaling, including both pro- and anti-inflammatory molecules, and pro-apoptotic mediators.<sup>12</sup> Chemokine-mediated lymphocyte recruitment and subsequent infection of lymphocytes, which also express ACE-2, likely contributes to lymphocyte apoptosis, natural killer and B-cell suppression, and T-cell exhaustion, as noted by Qin *et al.*<sup>3</sup> These findings are consistent with clinical lymphopenia, which correlates with mortality.<sup>3</sup> Viral injury, disordered cytokine release, and damage-associated molecular patterns (DAMPs) induce localized microvascular inflammation, which triggers endothelial activation, leading to vasodilation and pro-thrombotic conditions.

Angiotensin-II (AngII) is primarily metabolized by endothelial ACE-2 to the vasodilatory and anti-inflammatory peptide angiotensin(1-7). In the early phases of infection, ACE-2 consumption by viral entry would be predicted to increase local AngII concentration. Among the known effects of AngII are vasoconstriction, endothelial activation, and pro-inflammatory cytokine release. Platelet activation by AngII may further enhance a pro-thrombotic milieu. Ang-II also has potent chemotactic effects that may accelerate lymphocyte recruitment and suppression. Importantly, admission AngII levels in

COVID-19 patients are reportedly twice the normal levels.<sup>13</sup> In addition, pulmonary vascular inflammation specifically leads to a phenomenon known as ACE-1 “shedding”, where endothelial surface-bound ACE-1 is released into the interstitium.<sup>14</sup> This phenomenon initially produces a sharp increase in local AngII that gradually decreases until concentrations are well below physiologic levels.<sup>14</sup> Because AngII downregulates ACE-2 expression, transition to a state of AngII deficiency is consistent with the increased ACE-2 expression noted at autopsy.<sup>10</sup> Of note, AngII reportedly increases microvascular permeability under basal conditions but decreases permeability during inflammation, an effect attributed to the inflammation-induced shift from type-1 to type-2 receptor expression.<sup>15</sup>

## **IMPLICATIONS FOR THERAPEUTICS AND RESEARCH**

Postulating that COVID-19 is a vascular and hypo-inflammatory disease has important implications for ongoing research. However, more evidence is needed to explore vascular injury through biomarkers, imaging and histology. If COVID-19 is indeed primarily a vascular disorder, early invasive mechanical ventilation should be initiated cautiously. Investigations should examine the impact of liberal versus restrictive invasive mechanical ventilation strategies.

We reiterate that there is no evidence that COVID-19 patients develop “cytokine storm”. This finding suggests that the use of cytokine-blockade agents should meet with skepticism in the absence of randomized evidence. However, anticoagulation should be a key priority for investigation.

Similarly, given the putative role of AngII deficiency, a randomized trial in COVID-19 patients who have progressed to shock is warranted. Illness progression may also be an effect-modifier, with

potential benefits of anti-inflammation and angiotensin-blockade earlier in critical disease and harms at later time points.

## **CONCLUSION**

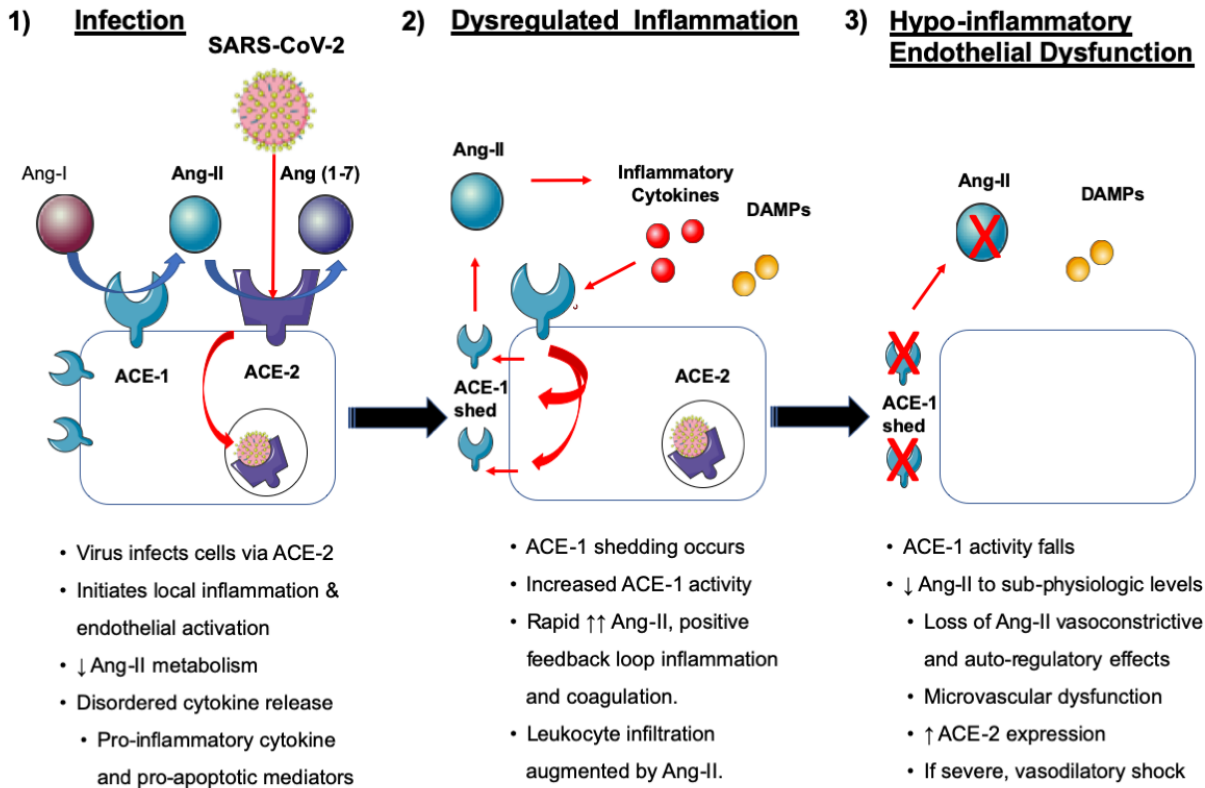
COVID-induced respiratory failure involves physiologic, clinical, and immunologic phenotypes that are not consistent with either ARDS or cytokine-release syndromes. COVID-19 instead reflects immunosuppression and features compatible with vascular disease.

**REFERENCES**

1. Gattinoni L, Coppola S, Cressoni M, Busana M, Chiumello D. Covid-19 Does Not Lead to a "Typical" Acute Respiratory Distress Syndrome. *Am J Respir Crit Care Med*. 2020.
2. Gattinoni L, Chiumello D, Caironi P, et al. COVID-19 pneumonia: different respiratory treatment for different phenotypes? *Intensive Care Med*. 2020; DOI 10.1007/s00134-020-06033-2
3. Qin C, Zhou L, Hu Z, et al. Dysregulation of immune response in patients with COVID-19 in Wuhan, China. *Clin Infect Dis*. 2020.
4. Sinha P, Delucchi KL, McAuley DF, O'Kane CM, Matthay MA, Calfee CS. Development and validation of parsimonious algorithms to classify acute respiratory distress syndrome phenotypes: a secondary analysis of randomised controlled trials. *Lancet Respir Med*. 2020;8(3):247-257.
5. Maude SL, Frey N, Shaw PA, et al. Chimeric antigen receptor T cells for sustained remissions in leukemia. *N Engl J Med*. 2014;371(16):1507-1517.
6. Caruso D, Zerunian M, Polici M, et al. Chest CT Features of COVID-19 in Rome, Italy. *Radiology*. 2020:201237.
7. Chen J, Wang X, Zhang S, et al. Findings of Acute Pulmonary Embolism in COVID-19 Patients (3/1/2020). 2020;SSRN.
8. Tian S, Hu W, Niu L, Liu H, Xu H, Xiao SY. Pulmonary Pathology of Early-Phase 2019 Novel Coronavirus (COVID-19) Pneumonia in Two Patients With Lung Cancer. *J Thorac Oncol*. 2020.
9. Zhang Y, Xiao M, Zhang S, et al. Coagulopathy and Antiphospholipid Antibodies in Patients with Covid-19. *N Engl J Med*. 2020.
10. Su H, Yang M, Wan C, et al. Renal histopathological analysis of 26 postmortem findings of patients with COVID-19 in China. *Kidney International*.
11. Liu Z, Xiao X, Wei X, et al. Composition and divergence of coronavirus spike proteins and host ACE2 receptors predict potential intermediate hosts of SARS-CoV-2. *J Med Virol*. 2020.
12. Fehr AR, Perlman S. Coronaviruses: an overview of their replication and pathogenesis. *Methods Mol Biol*. 2015;1282:1-23.
13. Liu Y, Yang Y, Zhang C, et al. Clinical and biochemical indexes from 2019-nCoV infected patients linked to viral loads and lung injury. *Sci China Life Sci*. 2020;63(3):364-374.
14. Nukiwa T, Matsuoka R, Takagi H, Ishii Y, Arai T, Kira S. Responses of serum and lung angiotensin-converting enzyme activities in the early phase of pulmonary damage induced by oleic acid in dogs. *Am Rev Respir Dis*. 1982;126(6):1080-1086.
15. Ereso AQ, Ramirez RM, Sadjadi J, et al. Angiotensin II type 2 receptor provides an endogenous brake during inflammation-induced microvascular fluid leak. *J Am Coll Surg*. 2007;205(4):527-533.





**Figure****Legend:**

1) The SARS-CoV-2 virus infects an endothelial cell by binding to ACE-2. Cellular infection initiates localized inflammation, endothelial activation, tissue damage, and disordered cytokine release. Membrane fusion also interrupts Ang-II metabolism, leading to an increase in Ang-II and a decrease in Ang(1-7), augmenting inflammation, endothelial activation, and leukocyte and platelet recruitment.

2) Pulmonary endothelial activation leads to the ACE-1 shedding phenomenon, where ACE-1 is rapidly liberated from the cell membrane. This produces an initial rapid rise in Ang-II, which can

induce a positive feedback loop enhancing local inflammation, coagulation, and capillary leak. 3) The transiently increased ACE-1 dissipates, leading to sub-physiologic Ang-II concentrations. Low Ang-II in this phase leads to vasodilation, worsened capillary leak, and impaired endothelial conductance and auto-regulation. Low systemic ang-II also upregulates ACE-2, possibly increasing susceptibility to SARS-CoV-2 in remote tissue.

Abbreviations: ACE – angiotensin-converting enzyme; Ang-I – angiotensin-I; Ang-II – angiotensin-II; Ang(1-7) – angiotensin(1-7); DAMPs – damage-associated molecular pattern molecules.

Supplementary Table:

<b>Supplemental Table – Comparison of COVID-19 with Systemic Vasculopathies</b>		
<b><u>Features</u></b>	<b><u>Common findings in vasculitidies</u></b>	<b><u>Severe CoViD-19</u></b>
Infectious Triggers	Many known viral triggers: Hepatitis B/C, Varicella, HIV, Epstein-Barr Virus, Cytomegalovirus, SARS-CoV-1	SARS-CoV-2
Lung	vascular inflammation.	Organizing pneumonia, modest peri-vascular inflammation.
Reported organ involvement	CV, neuro, GI, renal, skeletal muscle	Cardiomyopathy, renal, gastrointertinal Anosmia, Delirium
Thrombotic events	Arterial / venous involvement. (Varies by specific disease).	Massive d-dimer elevations that correlates with death.  DVT, pulmonary embolism, catheter thrombosis

Systemic inflammation	Mildly elevated inflammatory cytokines. (IL-6 generally < 100) Acute Phase Reactants: High CRP, ESR, Ferritin. Low albumin.	Mildly elevated inflammatory cytokines (IL-6 generally < 100) Acute Phase Reactants: High CRP, ESR, Ferritin. Low albumin, PCT
-----------------------	--	--

Abbreviations: HIV – Human immunodeficiency virus; CRP – C-reactive protein; ESR – erythrocyte sedimentation rate; PCT – procalcitonin; ECMO – extra-corporeal membrane oxygenation; DVT – deep venous thrombosis